



Journal Homepage: -www.journalijar.com

INTERNATIONAL JOURNAL OF ADVANCED RESEARCH (IJAR)

Article DOI:10.21474/IJAR01/14760
DOI URL: <http://dx.doi.org/10.21474/IJAR01/14760>



RESEARCH ARTICLE

GIANT OVARIAN DERMOID CYST - CASE REPORT

Dr. Banwari Lal Bairwa and Dr. Gupta Shubham Lalbabuprasad

Manuscript Info

Manuscript History

Received: 19 March 2022

Final Accepted: 25 April 2022

Published: May 2022

Key words:-

Dermoidcyst, Ovarian Mass,
Laparotomy

Abstract

The most prevalent type of ovarian germ cell tumour is dermoid cysts, also known as mature cystic teratoma. Dermoid cysts are benign germ cell tumours that account for 10–25% of all ovarian tumours and are bilateral in 10%–15% of cases. They are most common in reproductive-age women, although they can also be detected in postmenopausal women, and they are usually asymptomatic. Torsion, rupture, chemical peritonitis, and malignant transformation can all aggravate it, but infection is unlikely.

Copy Right, IJAR, 2022,. All rights reserved.

Introduction:-

Dermoid cysts, also referred to as benign mature teratomas, are the most common primary ovarian neoplasm and account for 10% to 25% of all ovarian neoplasms⁽¹⁾. It's mostly seen in patients between 20-40 years of age. Most patients presenting with dermoids are generally asymptomatic, however ovarian torsion, peritonitis due to rupture, bowel obstruction, spillage of sebaceous contents and malignant transformation can occur⁽²⁾. In 10% cases, they are bilateral, usually unilocular with smooth surface, contains sebaceous materials well as hair, lined in part by squamous epithelium⁽¹⁾. It also contains structures such as teeth, fluid or skin glands that can be located on or in the skin. Sometimes the sebaceous material accumulates together in the form of pellets. In certain cases, especially when in the ovary, it also contains thyroid or brain tissue.

Complications of dermoid cyst are Torsion as Dermoids are notorious for torsion (15%) because of their long pedicle and (heavy) weight (due to fat). It may also Rupture however spontaneous rupture is rare as their thick cyst wall resists rupture compared with other ovarian neoplasms. But if it does rupture, it might lead to a very serious chemical peritonitis which is usually dangerous. Peritonitis is generally attributed to sebum and hair contents of the cyst. When there is Chronic leakage of teratoma contents, it leads to granulomatous peritonitis that may be again interpreted as widespread malignancy⁽¹⁴⁾. It's Recurrence rate is usually 3–4%. However Malignancy is rare which accounts for 1.7% usually squamous cell carcinoma and rarely malignant thyroid tumours⁽⁷⁾.

However, A conservative surgical approach is of prime importance in a young patient with an aim to preserve ovarian function and future fertility. Preoperative evaluation of the adnexal mass and the proper choice of operative techniques are important in order to reduce intraoperative complications post surgery and preserve ovarian tissue. However, With improved and advanced laparoscopic surgical skills and instrumentation, the laparoscopic management of all dermoid ovarian cyst is now gaining acceptance and importance⁽⁸⁾. But in a large dermoid ovarian cyst, laparotomy is preferred over laparoscopy in order to avoid spillage with subsequent risk of chemical peritonitis and adhesions⁽¹³⁾.

Corresponding Author:- Dr. Banwari Lal Bairwa

Case Presentation

She was a 30-year-old, who presented to the gynaecological clinic with the history of abdominal mass and one-week history of lower abdominal pain. In any other area of the body, there was no bulk. Early satiety and belly bloating were linked, although there was no vomiting, bowel changes, weight loss, intermenstrual haemorrhage, leg edema, or lower limb varicosity. She has never had any medical or surgical issues before. There had been no previous such complaints in the family.

A general examination revealed a young woman who was not in any pain, was not pale, was anicteric, and had no lymphadenopathy or pedal oedema.

A 26-week size firm non-tender mass with smooth surface palpable on systemic examination of Per abdomen. Upper and lateral borders well delineated. The lower border is not discernible. There is limited transverse movement. Over mass, there is no commotion. There are no ascites. A tumor distinct from the uterus was discovered during a vaginal examination.

The rectal mucosa was free on rectal examination, and the same firm lump was felt anteriorly.

Routine investigations were within normal limits

The CA 125 level was 176 IU/ml, which was within normal limits. The results of the whole blood count, serum electrolytes, urea, creatinine, and liver function tests were all normal.

A right side ovarian tumor measuring 22*20 cm was discovered on a pelvic ultrasound examination, with mixed echogenicity, fat, fluid contents, and numerous septations. The left /Right ovary was unilocular and had mixed echogenicity. The uterus was normal in size and anteverted. There were no signs of ascites.

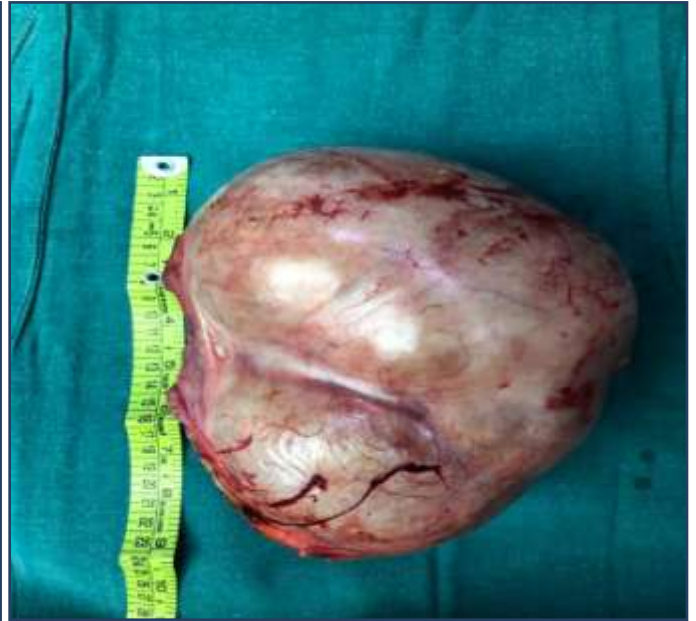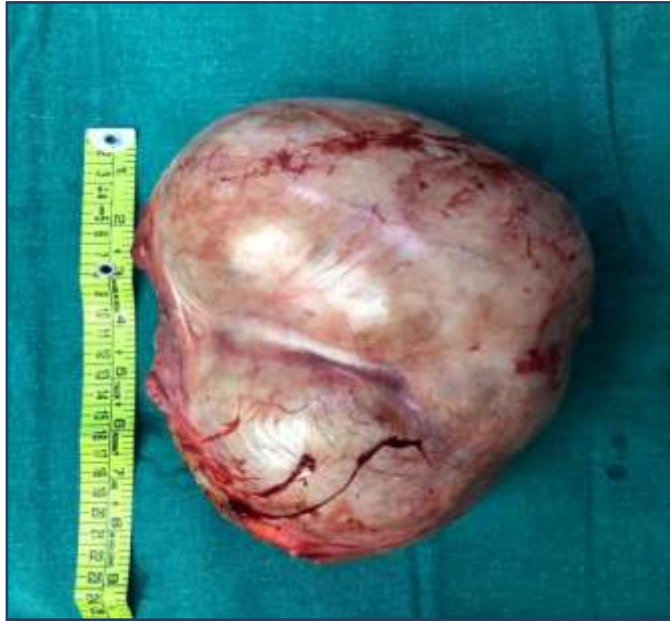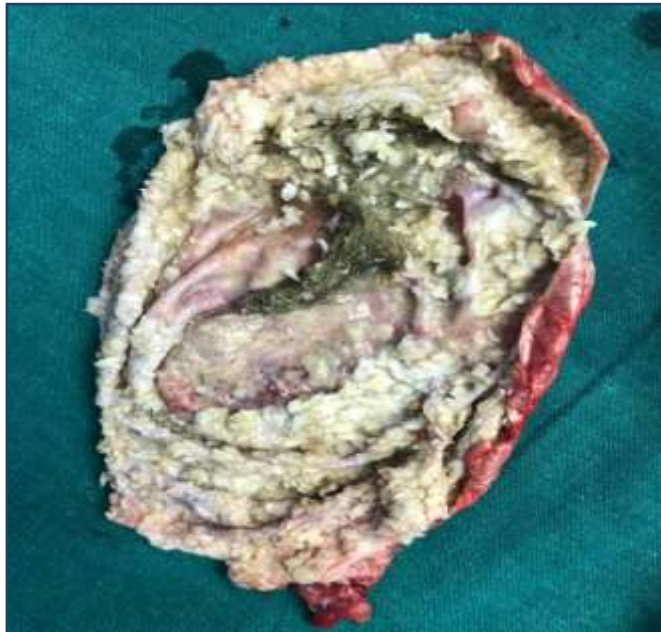
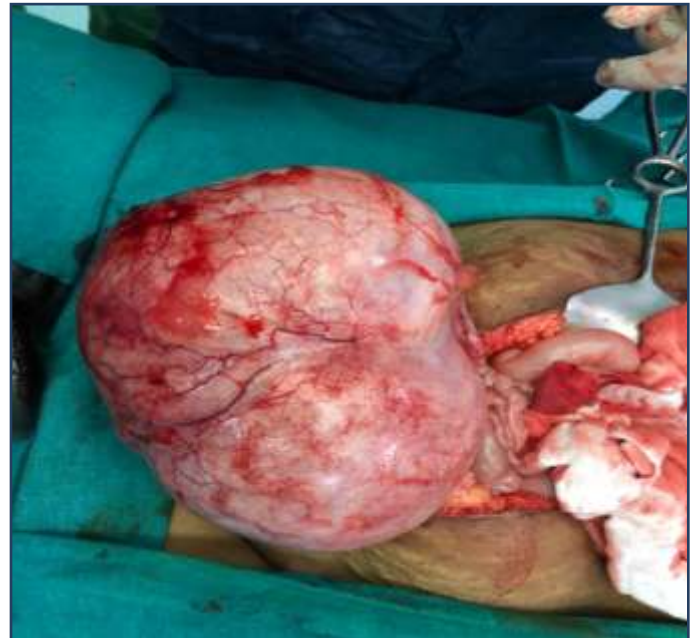The right adnexectomy revealed a unilocular cystic look with grey putty-like substance intertwined with abundant of hair on macroscopic inspection. The ovary was covered by fake membranes and pus, and the inner side of the cyst wall was hard, greyish brown, with hair emerging at points measuring 11*9 cm.

A mature dermoid cyst is surrounded by a huge polymorphic inflammatory reaction of altered and non-altered neutrophil polynuclear cells, lymphocytes, plasma cells, and macrophages on histological inspection.

The ultrasound findings were confirmed by a multidimensional CT scan of the abdomen and pelvis.

An Unilateral ovarian cyst was discovered. She was advised about the findings and diagnosis, as well as the need for an exploratory laparotomy.

Informed written consent was obtained. The anesthesiologist was summoned to examine her, and surgery was scheduled.

Figures/Pictures:**Figure/ Picture : 01****Figure/ Picture : 02****Figure/ Picture : 03****Figure/ Picture : 04****Discussion:-**

Dermoid cysts, also known as mature cystic teratomas or dermoids, are benign germ cell tumours.(2) Dermoid cysts are the most common ovarian tumours generally occurring in the second and third decade of life. The prevalence of Giant ovarian cysts is less in current medical practice in both developed and developing nations. The same is attributed to the widespread use of modern imaging techniques such as ultrasound and CT.(3,4) Most women with dermoid cysts are asymptomatic. If at all present, their signs and symptoms generally depend upon the size of the mass. Giant dermoid cysts have only been documented seldom in the literature.They are much more likely to cause complications such as torsion and rupture.(5)

Dermoid cysts are frequently being misdiagnosed as true ovarian cysts(4). Proper Knowledge of the structure and contents of dermoid cysts is an important prerequisite to the understanding of their pathology and radiographic appearance. The tumors are generally cystic or loculated sometimes, and may vary from a few millimeters in diameter to the size of a melon. Their cystic nature distinguishes them from teratomas, however this distinction cannot usually be recognised solely on the basis of histology⁽⁹⁾. Since they are difficult to diagnose preoperatively, they are usually found incidentally during abdominal surgery hence The management of MCTs in the adolescent population poses unique challenges given the potential impact on sexual development and fertility. Large quantities of fat attenuation within an ovarian lesion, with or without calcification in the cyst wall, are CT findings that suggest teratomas.

On MRI, the sebaceous component of dermoid cyst parallels the signal intensity of fat on all sequences.(8)There are many imaging modalities but The sensitivity of MRI is nearly 100% in ovarian dermoid mass(9) however the proper diagnosis is made at the time of surgical excision. Ovarian tumors account for approximately 1% of all neoplasms in children and adolescents, and 75% to 85% of such lesions are benign(1).Ovarion Dermoid mass requires Resection as they possess higher risk of Malignancy. Conventional treatment of giant ovarian cysts usually consist of full midline laparotomy, followed by a cystectomy or oophorectomy.Hence Laparoscopic management of Giant ovarian dermoid tumours is a safe and efficient procedure .It does not raise the risk of problems when compared to the open technique, and it allows for a shorter hospital stay, faster recuperation, and, most importantly, conservative treatment, particularly in premenopausal women who desire to become pregnant. (10) Removing cysts in an endobag significantly reduced both operating time and spillage. However, controlled intraperitoneal spillage of cyst contents does not increase postoperative morbidity as long as the peritoneal cavity is thoroughly washed.(13) If spillage occurs,There is chances of peritonitis hence complete removal of spilled contents and copious irrigation should be performed to avoid peritonitis.(12)

Conclusion:-

Ovarian tumours are generally accompanied by a variety of symptoms. To avoid any problems, early detection and management are required.In the therapy of this ailment, excision alone is frequently sufficient.

Reefrences:-

1. Hakim MM, Abraham SM. Bilateral dermoid ovarian cyst in an adolescent girl. *BMJ Case Rep.* 2014. Available from: <https://www.ncbi.nlm.nih.gov/pmc/articles/PMC4112312/doi:10.1136/bcr-2014-205236> (Accessed 10 November, 2019).
2. Kurman RJ (2002) Blaustein's Pathology of the Female Genital Tract. Springer Verlag 967-1033
3. Suntharasaj T, Sriwongpanich S, Sorapipat C. The largest ovarian cyst in Songklanagarind Hospital: a case report. *J Med Assoc Thai* 1994;77(8):445-448.
4. Symmonds RE, Spraitz AF, Koelsche GA. Large Ovarian Tumor. Report of a Case. *ObstetGynecol* 1963; 22:473-477
5. Abbas AM, Gamal E, Talaat E, Sheha AM. Torsion of huge dermoid cyst in adolescent girl: a case report. *Middle East Fertil Soc J.* 2017 Sep;22(3):236-9. <https://doi.org/10.1016/j.mefs.2017.01.003>
6. Brown MF, Hebra A, McGeekin K, Ross AJ III. Ovarian masses in children: a review of 91 cases of malignant and benign masses. *J Pediatr Surg.* 1993;28(7):930-933.
7. Hassan E, Creatsas G, Deligeorlgou E, Michalas S. Ovarian tumors during childhood and adolescence: a clinicopathological study. *Eur J Gynaecol Oncol.* 1999;20(2):124-126.
8. Choudhary S, Fasih N, Mc Innes M, et al. Imaging of ovarian teratomas: appearances and complications. *J Med Imaging Radiat Oncol.* 2009;53:480-488.
9. Takeda A, Imoto S, Mori M, Yamada J, Nakamura H. Early abdominal pregnancy complicated by parasitic dermoid cyst: diagnosis by diffusion-weighted magnetic resonance imaging and management by laparoendoscopic single-site surgery. *J Minim Invasive Gynaecol.* 2012;19(5):647-50.
10. Dolan MS, Boulanger SC, Salameh JR, Laparoscopic management of giant ovarian cyst *JSLs* 2006 10(2):254-56.
11. Mülayim B, Gürakan H, Da-lı V, Mülayim S, Aydın O, Akkaya H, Unaware of a giant serous cyst adenoma: a case report *Arch GynaecolObstet* 2006 273:381-83.
12. Târcoveanu E, Vasilescu A, Georgescu S, Dănilă N, Bradea C, Lupascu C, Cotea E, Crumpei F, Vintili D, Motoc-Vieriu R, Dimofte G. Laparoscopic approach to ovarian dermoid cysts. *Chirurgia (Bucur).* 2012 Jul-Aug;107(4):461-8. PMID: 23025112.

13. Campo S, Garcea N. Laparoscopic conservative excision of ovarian dermoid cysts with and without an endobag. *J Am Assoc GynecolLaparosc.* 1998 May;5(2):165-70. doi: 10.1016/s1074-3804(98)80084-4. PMID: 9564065.
14. Hakim MM, Abraham SM. Bilateral dermoid ovarian cyst in an adolescent girl. *BMJ Case Rep.* 2014 Jul 10;2014:bcr2014205236. doi: 10.1136/bcr-2014-205236. PMID: 25012889; PMCID: PMC4112312.
15. Rebecca Yuan Li, Yogesh Nikam, SupuniKapurubandara, "Spontaneously Ruptured Dermoid Cysts and Their Potential Complications: A Review of the Literature with a Case Report", *Case Reports in Obstetrics and Gynecology*, vol. 2020, Article ID 6591280, 9 pages, 2020. <https://doi.org/10.1155/2020/6591280>.