

Contents lists available at [ScienceDirect](https://www.sciencedirect.com)

## International Journal of Surgery Case Reports

journal homepage: [www.casereports.com](http://www.casereports.com)

## Gossypiboma-an unusual cause of surgical abdomen and surgeon's nightmare: A rare case report

Banwari lal Bairwa\*

Department of Surgery, MP Birla Hospital and Research Centre, Chittorgarh, India

## ARTICLE INFO

## Article history:

Received 23 December 2020

Received in revised form 5 January 2021

Accepted 9 January 2021

Available online 3 February 2021

## Keywords:

Case report

Gossypiboma

Intestinal obstruction

Surgical abdomen

Exploratory laparotomy

## ABSTRACT

**INTRODUCTION:** The term Gossypiboma is used to describe a retained surgical sponge in body after surgical procedure. It is an infrequent but serious surgical complication which is seldom reported because of the medicolegal implications. It can present within days as a surgical emergency or years after the operation. **CASE PRESENTATION:** We report a case of 30-year-old female who presented in emergency with acute pain abdomen and severe distention of abdomen. She had history of caesarean section 15 days ago at another hospital. On clinical examination and investigation, it appeared like a surgical abdomen. Contrast enhanced computed tomography suspected an intrabdominal Gossypiboma. On exploratory laparotomy there was a lump in left side of abdominal cavity. Retained surgical sponge was removed that confirmed the diagnosis of Gossypiboma.

**DISCUSSION:** Gossypiboma is a real, serious but preventable surgical complication. It affects the patient safety, cost of treatment and may cause mortality if there is delay in diagnosis and treatment. It is commonly seen in emergency and difficult surgeries. Its clinical presentation is extremely variable. It can cause acute surgical abdomen, that needs urgent surgical intervention.

**CONCLUSION:** Meticulous counts of surgical items with careful inspection of surgical site can lessen these complications. Radio frequency chip identification verification by barcode scanner can reduce the error rate.

© 2021 The Author. Published by Elsevier Ltd on behalf of IJS Publishing Group Ltd. This is an open access article under the CC BY-NC-ND license (<http://creativecommons.org/licenses/by-nc-nd/4.0/>).

## 1. Introduction

Gossypiboma term was first described by Wilson in 1884 for unknowingly left surgical gauge or sponge in the body cavity after a surgical procedure [1]. The term Gossypiboma is derived from a Latin word "Gossypium" that is cotton and Swahili word "boma" that means place of concealment [2]. Usually, it causes exudative inflammatory reaction with formation of abscess, or aseptic fibrosis to develop a mass that leads to future complications like intestinal obstruction [3].

We will present a case of Gossypiboma causing surgical abdomen. The fellow paper was based on SCARE criteria 2020 [4].

## 2. Case presentation

A 30-year-old female patient presented in emergency department with chief complains of pain abdomen, distension of abdomen since last 3 days. Pain and abdominal distension aggravated by food and accompanied with nausea and vomiting for 2 days. She

was unable to pass stool and flatus since last 3 days. She had recurrent vomiting and intermittent fever for two days. She underwent emergency lower segment caesarean section 15 days back in other hospital. After caesarean section surgery she experienced abdominal discomfort, bloating, nausea and gradually developed abdominal pain and distension in post-operative period but managed conservatively and discharged from the hospital. Absence of history of addiction and other comorbidities.

On examination vital signs were BP:100/70 mmHg, PR:112/min, RR:22/min. On abdominal examination tenderness was present all over abdomen more on left side and distension of abdomen was present. On auscultation bowel sounds were exaggerated. There was a pfannenstiel scar in lower abdomen.

Her WBC was 17,400 (87% neutrophil). Abdominal X-ray (Fig. 1) showed significant distension of the intestinal loops, and air-fluid levels. On abdominal-pelvic CECT scan, a well-defined hetero dense lesion in left lumbar region measuring 6.2 cm × 6.1 cm with air density foci within forming mottled appearance (Fig. 2a & b).

She was planned for exploratory laparotomy with diagnosis of acute intestinal obstruction, suspicious of Gossypiboma. Surgery performed by chief surgeon Dr Banwari lal Bairwa at MP Birla hospital and research centre Chittorgarh, India. On exploratory laparotomy, small bowel was grossly distended and lump of small

\* Present/permanent address: Flat no 403, Housing Complex, MP Birla Hospital, Senth Chittorgarh, Rajasthan, 312025, India.

E-mail address: [drbanwaribairwa@gmail.com](mailto:drbanwaribairwa@gmail.com)

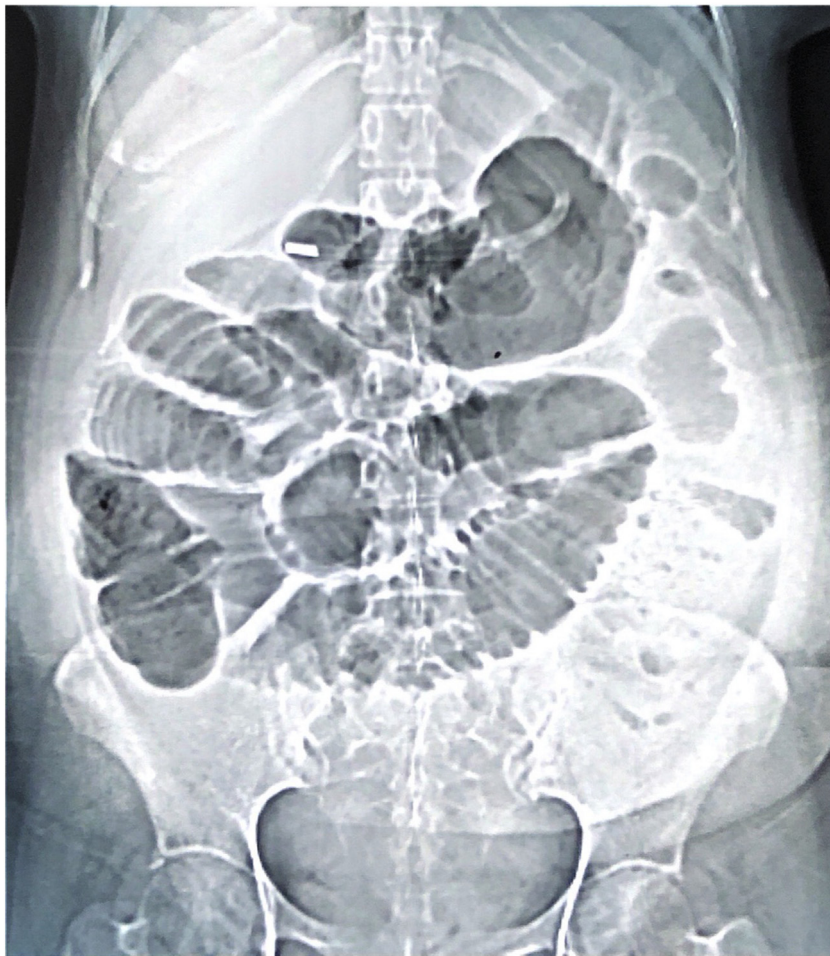

Fig. 1. Simple abdominal radiograph showing signs suggestive of intestinal obstruction.

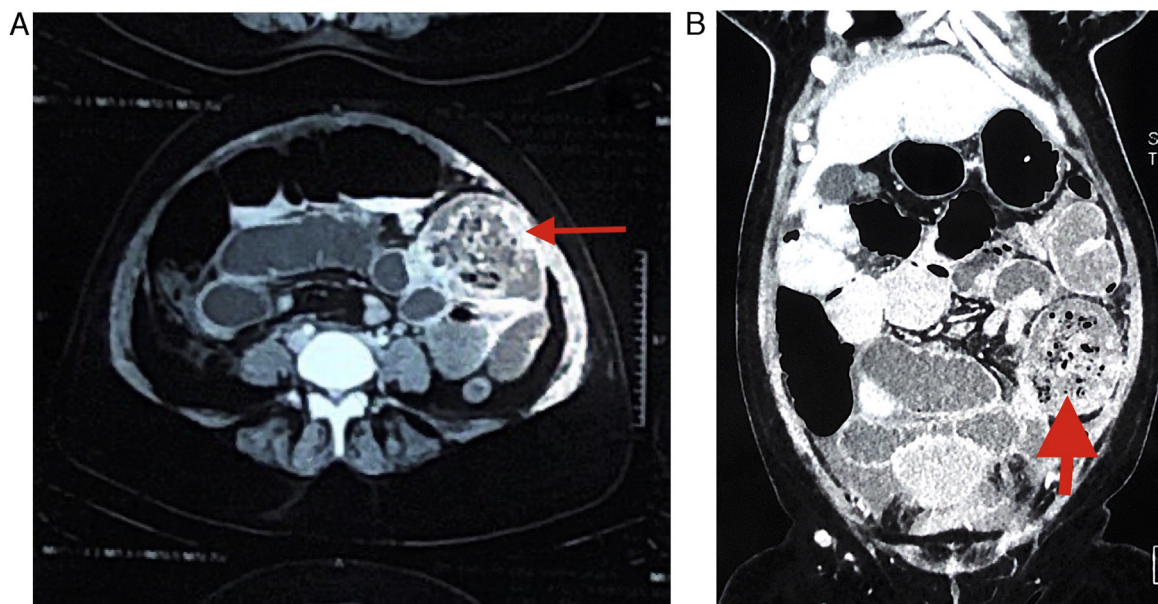
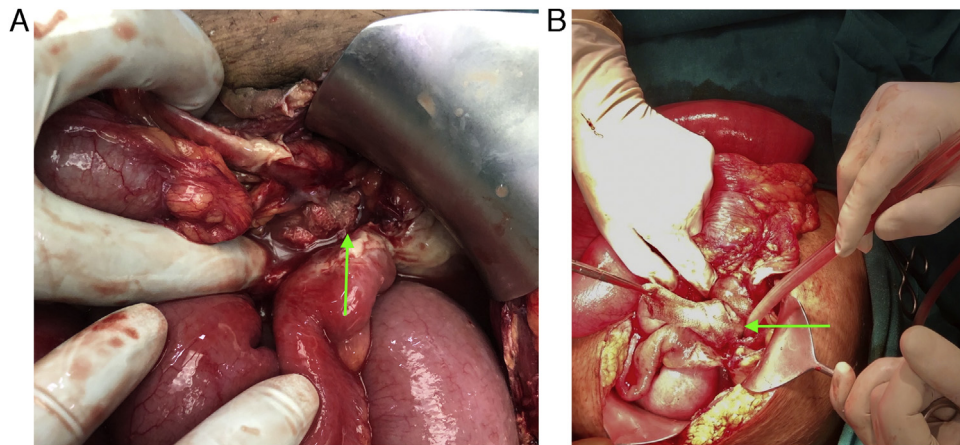


Fig. 2. a & b: CECT of abdomen showing well circumscribed mass with spongiform mottling appearance suggestive of foreign body (arrow).



**Fig. 3.** a & b: Intraoperative photograph showing retained surgical sponge in lump of bowel and omentum (arrow).

intestine, omentum, descending colon and retained surgical sponge was present in left quadrant (Fig. 3a and b).

500 mL pus drained. Meticulously dissection done, retained surgical sponge was removed and diagnosis of Gossypiboma confirmed. The abdomen was closed with all precautions and counts of surgical items.

Post-operative period was uneventful and discharged on 8th post-op day under satisfactory condition. On follow up at 15th post op day, there was no complaint. On follow up for 6months patient was doing well.

### 3. Discussion

An acute surgical abdomen needs emergent evaluation and urgent surgical intervention likely emergency exploratory laparotomy. Perforation peritonitis, intestinal obstruction, acute mesenteric ischemia, cholecystitis, diverticulitis, appendicitis, acute pancreatitis, ovarian torsions etc can be the cause of acute surgical abdomen. Unexplained pain, abdominal distension and fever in the post-operative period should lead one to suspect a retained foreign body. In our case patient diagnosed with acute intestinal obstruction probably due to retained postoperative foreign body and presented with signs of acute surgical abdomen. Gossypiboma is a real, serious but preventable surgical complication. It affects the patient safety, cost of treatment and may cause mortality if there is delay in diagnosis and treatment.

The incidence of retained surgical items such as surgical mop, needle, or any part of instrument following surgery is 0.01%–0.001%. Gossypiboma is major chunk out of all these foreign bodies, that is 80% of cases [5]. Gossypiboma is commonly seen in cases of emergency surgery, prolonged and difficult surgeries, unexpected change in surgical procedure, disorganization of surgical team, poor communication, change in surgical team or scrub nurse [2,3].

The retained surgical sponge can cause an exudative or fibrinous reaction in body. Exudative pattern appears early in the post-operative period because of local inflammation. Due to capsulation of retained foreign body, fibrinous response occurs later [6].

The clinical presentation of Gossypiboma is extremely variable and patients could present in a few days to more than 40 years from index surgery. The most commonly affected sites are abdomen (56%), pelvis (18%) and thorax (11%). Commonly presenting symptoms and sign are pain, palpable mass, abdominal distension, tenesmus, vomiting. Gossypiboma can cause complication like intestinal obstruction, abscess and fistula formation, sepsis or even death may occur [7].

CECT is the investigation of choice of Gossypiboma, showing well circumscribed capsulated mass with presence of air within and enhancement of the wall. Internal structure may appear as a spongiform or whirl like due to trapped air in the sponge and it may be of low density, low density and wavy, striped or spotted high density area [8]. Ultrasonography shows characteristic patterns as echogenic area with intense posterior shadow, hyperechoic wavy striped structure and hypoechoic or complex mass.

Surgery is the only treatment of Gossypiboma. Prevention of Gossypiboma is very important and can be done by a systemic approach. The American college of surgeons (ACS) and the association of registered nurse of USA recommends that counts should be performed at the various phases during surgery. Count must be performed prior to start of the surgery, at the time of addition of new item, prior to closure of cavity, at the time of closure of incision and at skin closure. If count is incorrect, it is the duty of the entire team to look for the missing item and thorough exploration of the surgical site should be done [9]. Electronic article surveillance system and the radiofrequency chip identification by barcode scanner, are new technologies that will help in prevention of Gossypiboma [10]. An effective surgical safety protocol like the WHO checklist can be used as the part of institutional policies that help to improve surgical safety and prevent complications like Gossypiboma [11].

### 4. Conclusions

Gossypiboma is serious but avoidable, postoperative complication. It must be prevented at all costs. It can cause significant morbidity for the patient. It has serious medicolegal implications and negative impact on medical fraternity. The surgeons should comply with the current recommendations on the prevention of retained surgical items. It is the collective responsibility of the surgical team, the nursing team, and operation theatre technicians to ensure the safety of the patient.

### Declaration of Competing Interest

The authors report no declarations of interest.

### Sources of funding

Author declare no source of funding.

### Ethical approval

This study was exempt from ethical approval at our institution.

**Consent**

The publication and dissemination of the case was authorized by the patient.

Written informed consent was obtained from the patient for publication of this case report and accompanying images. A copy of the written consent is available for review by the Editor-in-Chief of this journal on request.

**Author contribution**

Banwari lal Bairwa: chief surgeon, article writing, review and corresponding author.

**Registration of research studies**

Not applicable.

**Guarantor**

Banwari lal Bairwa.

**Provenance and peer review**

Not commissioned, externally peer-reviewed.

**References**

- [1] T. Ram, D. Dahiya, A. Naik, Gossypiboma: case report and review of literature, *Int. Surg. J.* 6 (2019) 4148–4151.
- [2] K.N. Srivastava, A. Agarwal, Gossypiboma posing as a diagnostic dilemma: a case report and review of the literature, *Case Rep. Surg.* 2014 (2014), 713428.
- [3] I. Lata, D. Kapoor, S. Sahu, Gossypiboma, a rare cause of acute abdomen: A case report and review of literature, *Int. J. Crit. Illn. Inj. Sci.* 1 (2011) 157–160.
- [4] R.A. Agha, T. Franchi, C. Sohrabi, G. Mathew, for the SCARE Group, The SCARE 2020 guideline: updating consensus Surgical Case Report (SCARE) guidelines, *Int. J. Surg.* 84 (2020) 226–230.
- [5] M.K. Garg, M.T. Zeya, U. Garg, S. Goyal, M. Yadav, Gossypiboma a diagnostic dilemma or medical negligence a case report, *J. Indian Acad. Forensic Med.* 36 (1) (2014) 100–103.
- [6] B.N. Alemu, A.G. Tiruneh, Gossypiboma: a case series and literature review, *Ethiop. J. Health Sci.* 30 (January (1)) (2020) 147.
- [7] S. Hempel, M. Maggard-Gibbons, D.K. Nguyen, A.J. Dawes, I. Mlake-Lye, J.M. Beroes, et al., Wrong-site surgery, retained surgical, items, and surgical fires a systematic review of surgical never events, *JAMA Surg.* 150 (8) (2015) 796–805, <http://dx.doi.org/10.1001/jamasurg.2015.0301>, PMID: 26061125.
- [8] C.F. Murphy, H. Stunell, W.C. Torreggiani, Diagnosis of gossypiboma of the abdomen and pelvis, *Am. J. Roentgenol.* 190 (June (6)) (2008) W382.
- [9] American College of Surgeons (ACS) Committee on Perioperative Care, Revised statement on the prevention of unintentionally retained surgical items after surgery, *Bull. Am. Coll. Surg.* 101 (2016) 50–51, PMID: 28937718.
- [10] A. Macario, D. Morris, S. Morris, Initial clinical evaluation of a handheld device for detecting retained surgical gauze sponges using radiofrequency identification technology, *Arch. Surg. Chic. Ill.* 1960 141 (2006) 659–662.
- [11] WHO, WHO Surgical Safety Checklist and Implementation Manual [Internet], 2016 <http://www.who.int/patientsafety/safesurgery/ss.checklist/en/>.

**Open Access**

This article is published Open Access at [sciencedirect.com](https://www.sciencedirect.com). It is distributed under the [IJSCR Supplemental terms and conditions](#), which permits unrestricted non commercial use, distribution, and reproduction in any medium, provided the original authors and source are credited.